



# Algorithmic approach to the lymphatic leak after vascular reconstruction: a systematic review

Peter John Nicksic, Kevin Michael Condit, Harry Siva Nayar, Brett Foster Michelotti

Division of Plastic and Reconstructive Surgery, University of Wisconsin Hospitals and Clinics, Madison, WI, USA

**Background** To date, there are no consensus guidelines for management of lymphatic leak in groin vascular reconstruction patients. The goal of this study is to review the relevant literature to determine alternatives for treatment and to design an evidence-based algorithm to minimize cost and morbidity and maximize efficacy.

**Methods** A systematic review of the literature was conducted per Preferred Reporting Items for Systematic Reviews and Meta-Analyses (PRISMA) protocol. Two independent reviewers applied agreed-upon inclusion and exclusion criteria to eligible records. Studies that included patients who underwent groin dissection for oncologic diagnoses and level 5 data were excluded. Interventions were then categorized by efficacy using predetermined criteria.

**Results** Our search yielded 333 records, of which eight studies were included. In four studies, the success of lymphatic ligation ranged from 75% to 100%, with average days to resolution ranging from 0 to 9. Conservative management in the form of elevation, compression, and bedrest may prolong time to resolution of lymphatic leak (14–24 days) and therefore cost.

**Conclusions** The majority of patients should be offered early operative intervention in the form of lymphatic ligation with or without a primary muscle flap. If the patient is not an operative candidate, a trial of conservative management should be attempted before other nonsurgical interventions.

**Keywords** Lymph / Lymphorrhea / Algorithms / Blood vessel prosthesis

**Correspondence:**

Brett Foster Michelotti  
Division of Plastic and Reconstructive  
Surgery, University of Wisconsin  
Hospitals and Clinics, 600 Highland  
Ave, Madison, WI 53792, USA  
Tel: +1-608-263-7502  
E-mail: michelotti@surgery.wisc.edu

Received: October 22, 2020 • Revised: April 26, 2021 • Accepted: May 25, 2021  
pISSN: 2234-6163 • eISSN: 2234-6171 • <https://doi.org/10.5999/aps.2020.02075> • Arch Plast Surg 2021;48:404-409

## INTRODUCTION

Lymphatic leak is a serious complication of vascular surgery that incurs significant cost to the healthcare system and morbidity to the patient [1-5]. Disruption of lymphatic channels during vascular surgery and failure of subsequent healing may result in persistent leakage, presenting as lymphocele or lymphocutaneous fistula, and may occur in as many as 18% of arterial interventions [6]. A variety of factors have also been identified that may predispose patients to lymphatic leak including surgical procedure and graft type, incision techniques, as well as patient

demographics [3,5,7]. As a result, patients who develop post-vascular dissection lymphatic leak have delayed wound healing, are at greater risk of infection and graft rejection, and spend more time in the hospital, thereby increasing the cost of care [2,5,6].

First-line interventions of lymphatic leak currently include both surgical strategies—primary muscle flaps, lymphatic ligation, and suction drain placement [8-11]—and nonoperative strategies—bed rest, elevation, compression, prophylactic antibiotics, vacuum assisted closure therapy, and glue embolization [9,12-14]. There are data to support each of these strategies,

however, there is no consensus regarding how to expeditiously resolve lymphatic complications.

The goal of this systematic review is to develop an evidence-based, cost-conscious, algorithmic approach to management of lymphatic leak after groin dissection for vascular reconstruction.

## METHODS

### Literature search

A systematic review was performed according to the Preferred Reporting Items for Systematic Reviews and Meta-Analyses (PRISMA) statement. The literature database was extracted by searching the Scopus, PubMed, and Cochrane Library databases on November 11, 2019. The search phrases used were combinations of “lymphatic leak,” “lymphorrhoea,” “lymphocele,” “groin surgery,” “axillofemoral bypass,” “femoral artery surgery,” “femoral endarterectomy,” and “femoral-popliteal bypass.” The studies included were English articles published between 1968 and 2018.

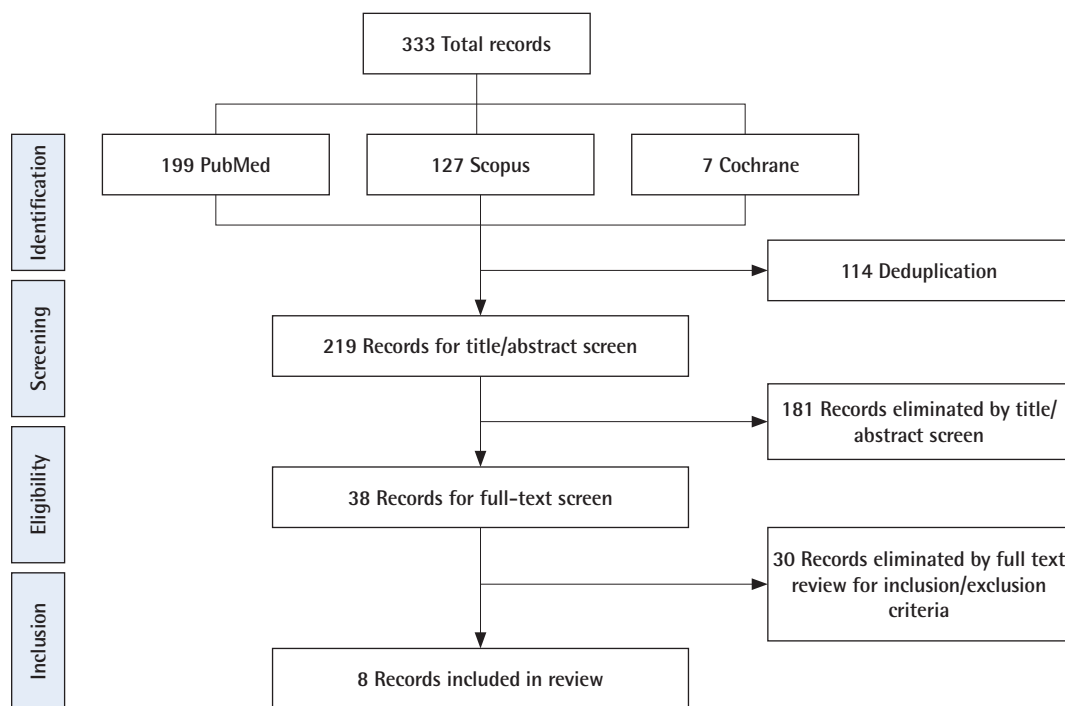
Studies included were randomized-controlled trials, cohort studies, case-control studies, and case series that pertain to the incidence, diagnosis, or treatment of lymphatic complications (i.e., lymphatic leak or lymphocele) after open groin dissections for the purpose of vascular reconstruction. We excluded studies with level five data (i.e., case reports, discussions, or expert opin-

ion), studies including data on groin dissection for indications other than vascular reconstruction, studies involving endovascular interventions or saphenous vein harvest, and studies that reported data only on lymphoceles without reporting data on lymphatic leak.

### Data collection and quality of recommendation assessment

Studies that met inclusion and exclusion criteria were then assessed by three independent reviewers. Data collected were year of publication, study design, level of evidence, number of patients, treatment modality, success rate of treatment described, and average days to successful treatment.

To evaluate strength of treatment recommendation, interventions described in the articles were categorized by efficacy. Success rate, days to resolution, level of evidence, consensus recommendation, and number of patients studied were used to compare studies. The treatment modalities that were supported by higher level evidence, were consensus recommendations from selected articles, and included robustly powered studies were given the designation of “efficacious.” These interventions were considered first-line treatments in the algorithm. To compare first-line treatments, the treatment with the lowest days to resolution and highest percent efficacy was favored. Treatment modalities that were supported by lower level evidence, were sub-



**Fig. 1.** Diagram of our included articles. Our query yielded 333 records, which after deduplication included 219 unique records. After screening for title and abstract by two independent reviewers, 38 records were read in full. After applying full inclusion and exclusion criteria, eight articles were included in our final review.

ject to conflicting recommendations in the selected articles, or were supported by low-powered studies were given the designation of “mixed efficacy.” Interventions with mixed efficacy were suggested as second-line treatments.

## RESULTS

### Literature search and study selection

Our literature search yielded 333 total records, and 219 were remaining after deduplication. These 219 records were screened by title and abstract for relevance, yielding 38 records eligible for full-text review. Of these 38 records, eight met inclusion and exclusion criteria and were included in the study (Fig. 1). Three retrospective cohort studies [3,12,15], and five case series [13, 14, 16-18] were included (Table 1).

### Interventions and strength of recommendation

Lymphatic ligation was found to be effective in the treatment of lymphatic leak in a total of four studies with a success rate of 75% to 100% and a range of average days to resolution of 0 to 9

[3,12,15,16]. The studies that supported treatment with lymphatic ligation comprised level 2 through 4 evidence and no studies found lymphatic ligation to be unsuccessful. Additionally, the total number of patients studied for lymphatic ligation was 71, which was the highest for all interventions. For these reasons, lymphatic ligation was categorized as “efficacious” and considered a first-line surgical treatment option (Table 2).

Conservative management, which consisted of bedrest, elevation, compression, and prophylactic antibiotics, was found to be effective in two studies with a success rate of 75% to 90% and a range of average range of days to resolution of 14 to 24 [3,12]. These studies were comprised of level 2 through 4 evidence and included 35 patients. Therefore, conservative management was designated as “efficacious” and considered the first-line nonsurgical treatment option in the algorithm. One study retrospectively compared early lymphatic ligation to conservative management, and days to resolution was  $9 \pm 3$  days for the operative group versus  $24 \pm 3$  days in the nonoperative group ( $P < 0.01$ ) [3,12]. Therefore, early operative intervention was favored over conservative management in the algorithm.

**Table 1.** The included studies

Author (year)	Study type	Intervention	Efficacy (%)	Days to resolution	No. of patients	Groin wounds
al-Salman et al. (1997) [15]	Retrospective cohort	Lymphatic ligation	100	0	4	4
Bounds and Endean (2018) [16]	Case series	Lymphatic ligation with intraoperative lymphatic mapping using lymphazurin	100	32.5	32	33
Greer et al. (2000) [13]	Case series	VAC therapy	100 (resolution)	30	2	3
Schwartz et al. (1995) [12]	Retrospective cohort	Lymphatic ligation with lymphazurin mapping versus bed rest, leg elevation, prophylactic antibiotics, compressive dressings	75	0	7	7
Shermak et al. (2005) [17]	Case series	Muscle flap	100	NR	27	34
Smolock et al. (2018) [14]	Case series	Ultrasound-guided intranodal N-butyl cyanoacrylate injection	80	7	10	10
Tyndall et al. (1994) [3]	Retrospective cohort	Bed rest, limb elevation, prophylactic intravenous antibiotics, and pressure dressings versus lymphatic ligation	90	9	28	28
Van den Brande et al. (2012) [18]	Case series	Reoperation and placement of suction drain	82.60	14	22	23

Listed are the eight included studies in our final review, alphabetized by author, including title, year of publication, journal, study type, and intervention studied (when applicable). VAC, vacuum assisted closure; NR, not recorded.

**Table 2.** The interventions with assignments by efficacy

Intervention	Type	Level of evidence	No. of studies	Consensus	Total number of patients	Success rate (%)	Days to resolution (average)	Designation of efficacy
Lymphatic ligation	Surgical	2	4	Yes	71	75–100	0–9	Efficacious
Primary muscle flap	Surgical	4	1	NA	27	100	NR	Mixed efficacy
Suction drain placement	Surgical	4	1	NA	22	82.60	14	Mixed efficacy
Conservative management	Nonsurgical	2	2	Yes	35	75–90	14–24	Efficacious
VAC therapy	Nonsurgical	4	1	NA	2	100	30	Mixed efficacy
Glue embolization	Nonsurgical	4	1	NA	7	80	7	Mixed efficacy

The intervention type (surgical vs. nonsurgical), level of evidence, number of studies which included the intervention, whether there was consensus in the literature with regard to the intervention’s efficacy, total number of patients studied, success rate, average days to resolution, and efficacy designation are included. VAC, vacuum assisted closure; NA, not applicable; NR, not recorded.

In one level 4 study including 22 patients, suction drain placement without lymphatic ligation was effective in 82.6% of patients with an average time to resolution of 14 days [18]. When compared to lymphatic ligation, there are fewer patients studied and lower quality evidence. For these reasons, suction drain placement was assigned “mixed efficacy” and lymphatic ligation was favored in the algorithm.

In a case series of 34 groin lymphatic complications, sartorius, gracilis, rectus abdominis, and rectus femoris muscle flaps were used both with and without with lymphatic ligation [17]. No days to resolution was reported, but this study demonstrated 100% resolution of lymphatic leak and lymphocele. Another level 2, retrospective cohort study of 58 patients demonstrated that prophylactic muscle flaps decreased the incidence of infection and wound breakdown in all patients undergoing open groin surgery [8]. This reduction in infection and wound breakdown (70% absolute risk reduction [ARR] and 42.4% ARR,  $P < 0.001$ , respectively) was highest in patients with risk factors like smoking, obesity, re-operative groins, and prosthetic graft material [8]. Patients who required salvage muscle flaps for groin complications were more likely to have two of the aforementioned risk factors ( $P = 0.0004$ ) [8]. There was no time to resolution reported. Primary muscle flap was supported by a single case series and considered a treatment with “mixed efficacy.”

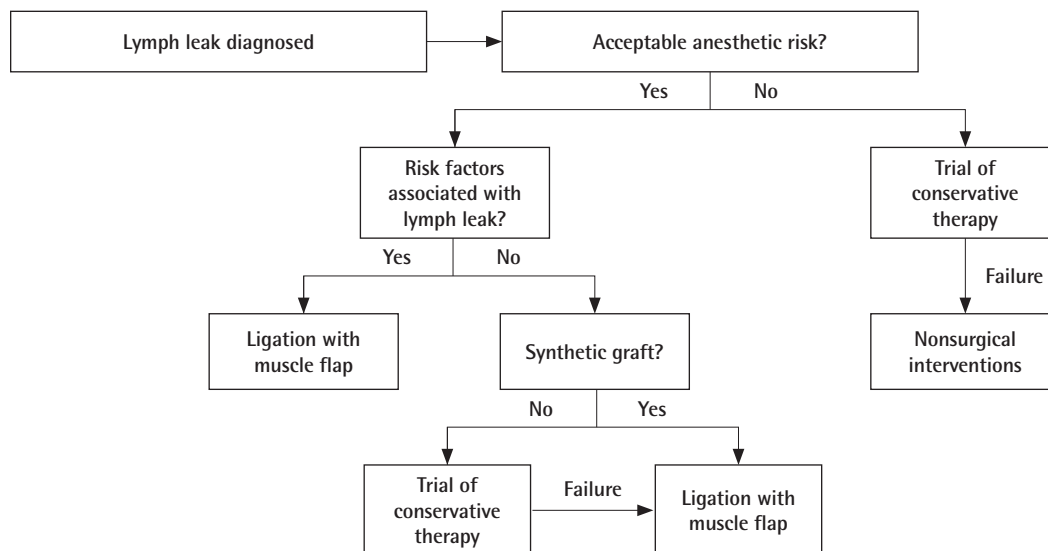
One small level 4 study found that vacuum assisted closure therapy was successful in two patients after an average of 30 days of treatment [13]. Interventional radiology glue embolization was found to be 80% successful in a 10-patient, level 4 study af-

ter a trial of failed conservative therapy. The time to resolution was an average of 7 days [14]. These interventions are supported by a single, small study with low-level evidence and were assigned “mixed efficacy.”

## DISCUSSION

These treatment modalities were synthesized into an algorithm to optimize efficacy and minimize morbidity. The first decision point in the algorithm is whether the patient should be treated operatively or non-operatively. In one retrospective, single-center study that compared operative versus nonoperative management for lymphatic leaks, lymphatic leaks that were managed with lymphatic ligation with intraoperative lymphatic mapping at the time of diagnosis resolved on average 13 days sooner than those that were treated conservatively ( $P < 0.01$ ) [3]. These results were corroborated in another, smaller retrospective study that demonstrated shorter hospital stay, fewer recurrences, and lower complication rates with lymphatic ligation aided by isosulfan blue [12]. For this reason, we recommend that most patients who are of acceptable anesthetic risk should undergo lymphatic ligation at the time of diagnosis instead of conservative management (Fig. 2).

Although primary muscle flap was considered a treatment with “mixed efficacy,” we recommend that a sartorius flap be included to augment lymphatic ligation. In a case series of 34 groin lymphatic complications, sartorius, gracilis, rectus abdominis, and rectus femoris muscle flaps were used in conjunction



**Fig. 2.** The evidence-based algorithm. The algorithm was designed to minimize morbidity and cost while maximizing efficacy in the management of the lymph leak patient. The majority of patients should receive early operative intervention, but a few, select patients without risk factors associated with lymphatic leak—aortobifemoral bypass graft, preoperative length of stay > 1 day, or re-operative groin—would benefit from conservative management.

with lymphatic ligation in 22 of the 34 complication sites. None of the patients who underwent flap surgery had recurrence of lymphocele or lymphatic leak after 1 year [17]. Additionally, flap biopsies were taken 1 year after the index operation in one of the patients. The transposed muscle demonstrated a significant increase in lymphatic channels, suggesting that the muscle itself becomes a vessel for lymphatic shunting [17]. A retrospective cohort study of 68 open groin operations also found that patients with two of the following risk factors: smoking, obesity, re-operative groins, and synthetic graft material, were associated with necessitating muscle flap salvage of their reconstruction [8]. While there are no studies that demonstrate that lymphatic ligation with primary muscle flap is superior to lymphatic ligation alone, we recommend primary sartorius flap at the time of lymphatic ligation because it is a low-morbidity operation that has been shown to decrease the risk for infection [8] and may reduce the risk of persistent lymphatic leak (Fig. 2).

While early operative intervention demonstrated a shorter time to resolution when compared to nonsurgical management, nonsurgical management was shown to be effective in the management of lymphatic leak, and some patients did not require a second operation to heal. This is an important consideration as reoperation on a reconstructed groin is not without risk and morbidity. There are no studies that demonstrate clear predictors of failure of conservative therapy in the literature. However, certain surgical and demographic risk factors predispose patients to lymphatic leak. In a retrospective study that included 2,679 groin dissections, procedure-related incidence of groin lymphatic complications were found to be significantly higher in redo operations and aortobifemoral bypass (ABFB) [3]. In a prospective study of 120 ABFB patients, patient factors like smoking, obesity, renal disease, and diabetes were not found to be associated with groin lymphatic complications. However, a preoperative length of stay greater than 1 day was associated with incisional complications of the groin (odds ratio, 3.94) [5]. Patients with these aforementioned risk factors—ABFB, redo operations, and preoperative length of stay greater than 1 day—should be considered high-risk for lymphatic leak. One limitation of this study is the inclusion of only open groin dissections for vascular reconstruction. We appreciate that the results of this study may not be applicable to endovascular surgery, or to saphenous vein harvest, in the setting of cardiac bypass surgery. These factors do not directly predict failure of nonsurgical management, but they may act as a surrogate to determine which patients require early operative intervention to heal their lymphatic leak (Fig. 2).

Another important factor that affects who would be appropriate for a trial of nonoperative management is the risk of serious infection. It has been established that synthetic grafts signifi-

cantly increase the risk of infection involving the arterial reconstruction when compared to autogenous vein grafts, endarterectomies, and arterial allografts [19]. We recommend against conservative management in patients with synthetic graft material as there is an unacceptable risk for infection involving the reconstruction (Fig. 2).

The concept of prophylactic muscle flaps for high-risk patients has been described [8]. Larger and more rigorous studies are needed to determine which patients might benefit from prophylactic muscle flaps, at the time of vascular reconstruction to prevent subsequent lymphatic leak. Additionally, there have been reports of microsurgical lymphaticovenous shunting in the treatment of lymphatic leak after lymph node excision in the groin [20]. This technically demanding operation shows promise to be a future treatment of lymphatic leak post-vascular reconstruction of the groin.

The available data support that early operative intervention in the form of lymphatic ligation with simultaneous muscle flap is the most efficacious and cost-effective treatment for lymphatic leak. If the patient is not an operative candidate, we recommend a 3-week trial of conservative management—bedrest, elevation, prophylactic antibiotics, and pressure dressing. If the lymphatic leak is not resolved at the end of the trial, procedural adjuncts like interventional radiology embolization may be utilized. It is also acceptable to attempt conservative management to reduce the morbidity associated with reoperation in patients without prosthetic material and who do possess risk factors associated with prolonged lymphatic leak. Due to its low incidence, it is difficult to identify the predictors of lymphatic complications. With the help of this algorithm, the reader may use evidence-based guidelines to minimize morbidity and cost while considering treatment efficacy and predictability of resolution in the lymphatic leak patient.

## NOTES

### Conflict of interest

No potential conflict of interest relevant to this article was reported.

### Author contribution

Conceptualization: PJ Nicksic, HS Nayar, BF Michelottii. Methodology: PJ Nicksic, KM Condit, HS Nayar. Writing - original draft: PJ Nicksic, KM Condit. Writing - review & editing: PJ Nicksic, BF Michelottii.

### ORCID

Peter John Nicksic <https://orcid.org/0000-0002-0577-8212>

Kevin Michael Condit

<https://orcid.org/0000-0002-2842-6738>

Harry Siva Nayar

<https://orcid.org/0000-0003-3130-7833>

Brett Foster Michelotti

<https://orcid.org/0000-0002-6166-1836>

## REFERENCES

1. Kent KC, Bartek S, Kuntz KM, et al. Prospective study of wound complications in continuous infrainguinal incisions after lower limb arterial reconstruction: incidence, risk factors, and cost. *Surgery* 1996;119:378-83.
2. Lv S, Wang Q, Zhao W, et al. A review of the postoperative lymphatic leakage. *Oncotarget* 2017;8:69062-75.
3. Tyndall SH, Shepard AD, Wilczewski JM, et al. Groin lymphatic complications after arterial reconstruction. *J Vasc Surg* 1994;19:858-64.
4. Soderman M, Thomsen JB, Sorensen JA. Complications following inguinal and ilioinguinal lymphadenectomies: a meta-analysis. *J Plast Surg Hand Surg* 2016;50:315-20.
5. Pejkcic S, Dragas M, Ilic N, et al. Incidence and relevance of groin incisional complications after aortobifemoral bypass grafting. *Ann Vasc Surg* 2014;28:1832-9.
6. Obara A, Dziekiewicz MA, Maruszynski M, et al. Lymphatic complications after vascular interventions. *Wideochir Inne Tech Maloinwazyjne* 2014;9:420-6.
7. Parikh PP, Rubio GA, Patel K, et al. Transverse versus longitudinal incisions for femoral artery exposure in treating patients with peripheral vascular disease. *Ann Vasc Surg* 2018;47:143-8.
8. Fischer JP, Nelson JA, Rohrbach JI, et al. Prophylactic muscle flaps in vascular surgery: the Penn Groin Assessment Scale. *Plast Reconstr Surg* 2012;129:940e-949e.
9. Healy DA, Keyser J 3rd, Holcomb GW 3rd, et al. Prophylactic closed suction drainage of femoral wounds in patients undergoing vascular reconstruction. *J Vasc Surg* 1989;10:166-8.
10. Dunlop MG, Fox JN, Stonebridge PA, et al. Vacuum drainage of groin wounds after vascular surgery: a controlled trial. *Br J Surg* 1990;77:562-3.
11. Weaver FA, Yellin AE. Management of postoperative lymphatic leaks by use of isosulphan blue. *J Vasc Surg* 1991;14:566-7.
12. Schwartz MA, Schanzer H, Skladany M, et al. A comparison of conservative therapy and early selective ligation in the treatment of lymphatic complications following vascular procedures. *Am J Surg* 1995;170:206-8.
13. Greer SE, Adelman M, Kasabian A, et al. The use of subatmospheric pressure dressing therapy to close lymphocutaneous fistulas of the groin. *Br J Plast Surg* 2000;53:484-7.
14. Smolock AR, Nadolski G, Itkin M. Intranodal glue embolization for the management of postsurgical groin lymphocele and lymphorrhea. *J Vasc Interv Radiol* 2018;29:1462-5.
15. al-Salman MM, Rabee H, Shibli S. Groin lymphorrhea postoperative nuisance. *Int Surg* 1997;82:60-2.
16. Bounds MC, Edean ED. Treatment of postoperative high-volume lymphatic complications using isosulfan blue. *J Vasc Surg Venous Lymphat Disord* 2018;6:737-40.
17. Shermak MA, Yee K, Wong L, et al. Surgical management of groin lymphatic complications after arterial bypass surgery. *Plast Reconstr Surg* 2005;115:1954-62.
18. Van den Brande P, von Kemp K, Aerden D, et al. Treatment of lymphocutaneous fistulas after vascular procedures of the lower limb: accurate wound reclosure and 3 weeks of consistent and continuing drainage. *Ann Vasc Surg* 2012;26:833-8.
19. Szilagyi DE, Smith RF, Elliott JP, et al. Infection in arterial reconstruction with synthetic grafts. *Ann Surg* 1972;176:321-33.
20. Giacalone G, Yamamoto T, Hayashi A, et al. Lymphatic supermicrosurgery for the treatment of recurrent lymphocele and severe lymphorrhea. *Microsurgery* 2019;39:326-31.