

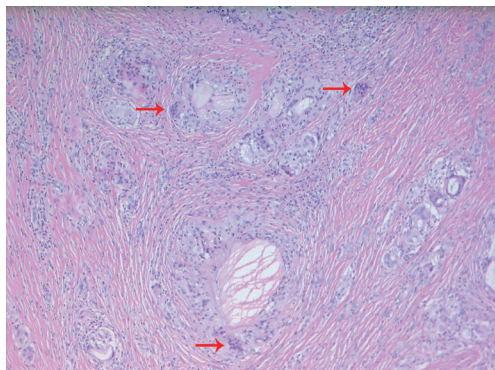Fig. 5. The histologic examination shows multinucleated giant cells (red arrows) suggestive of foreign body granuloma (H&E, $\times 100$).

them just had fluid accumulation and no foreign body granuloma. This rarity of the foreign body granuloma formation makes our case worthy of report.

In conclusion, although bioabsorbable implants have many advantages, we suggest paying considerable attention to their disadvantages such as their low strength and tendency to cause foreign body reactions. Moreover, hands require the ability to perform a large number of motions and need to have more extensive weight-bearing features than other body sites; therefore, bioabsorbable implants might not be appropriate for use in the treatment of hand fractures.

In conclusion, we suggest that a foreign body granuloma ought to be considered in the differential diagnosis of any mass occurring after the use of bioabsorbable implants in the treatment of metacarpal fractures.

References

1. Page SM, Stern PJ. Complications and range of motion following plate fixation of metacarpal and phalangeal fractures. *J Hand Surg Am* 1998;23:827-32.
2. Buijs GJ, van der Houwen EB, Stegenga B, et al. Mechanical strength and stiffness of biodegradable and titanium osteofixation systems. *J Oral Maxillofac Surg* 2007;65:2148-58.
3. Waris E, Ashammakhi N, Happonen H, et al. Bioabsorbable miniplating versus metallic fixation for metacarpal fractures. *Clin Orthop Relat Res* 2003;(410):310-9.
4. Bergsma EJ, Rozema FR, Bos RR, et al. Foreign body reactions to resorbable poly(L-lactide) bone plates and screws used for the fixation of unstable zygomatic fractures. *J Oral Maxillofac Surg* 1993;51:666-70.
5. Givissis PK, Stavridis SI, Papagelopoulos PJ, et al. Delayed foreign-body reaction to absorbable implants in metacarpal fracture treatment. *Clin Orthop Relat Res* 2010;468:3377-83.

Spontaneous Iliopsoas Hematoma: A Rare Complication of Anticoagulant Use

Sang Wha Kim¹, Dong Hwi Kim², Sung-No Jung²

¹Department of Plastic and Reconstructive Surgery, Seoul National University Hospital, Seoul National University College of Medicine, Seoul; ²Department of Plastic and Reconstructive Surgery, Uijeongbu St. Mary's Hospital, College of Medicine, The Catholic University of Korea, Seoul, Korea

Correspondence: Sung-No Jung
Department of Plastic and Reconstructive Surgery, Uijeongbu St. Mary's Hospital, College of Medicine, The Catholic University of Korea, 271 Chenbo-ro, Uijeongbu 480-717, Korea
Tel: +82-31-820-3576, Fax: +82-31-847-0301
E-mail: jsn7190@catholic.ac.kr

No potential conflict of interest relevant to this article was reported.

Received: 17 Mar 2015 • Revised: 13 May 2015 • Accepted: 18 May 2015
pISSN: 2234-6163 • eISSN: 2234-6171
<http://dx.doi.org/10.5999/aps.2015.42.4.507> • Arch Plast Surg 2015;42:507-510

Copyright © 2015 The Korean Society of Plastic and Reconstructive Surgeons
This is an Open Access article distributed under the terms of the Creative Commons Attribution Non-Commercial License (<http://creativecommons.org/licenses/by-nc/3.0/>) which permits unrestricted non-commercial use, distribution, and reproduction in any medium, provided the original work is properly cited.

Hemorrhage occurs in 4% of patients receiving anticoagulant therapy [1,2]. Most hemorrhages are located in intracranial and retroperitoneal lesions. In this report, we describe a case of iliopsoas hematoma in a patient treated by heparin salvage after finger replantation, which was treated conservatively.

A 53-year-old male patient suffered a crushing injury of the third finger. On physical examination, volar oblique amputation in zone I was observed (Fig. 1). The initial laboratory examination showed hemoglobin levels, white blood cell count, and activated partial thromboplastin time (aPTT) within normal ranges with stable vital signs. Emergency replantation was performed with anastomosis of one artery and one vein (Fig. 2). Postoperatively, 5,000 IU of heparin was continually administered intravenously every 24 hours. Five days after surgery,

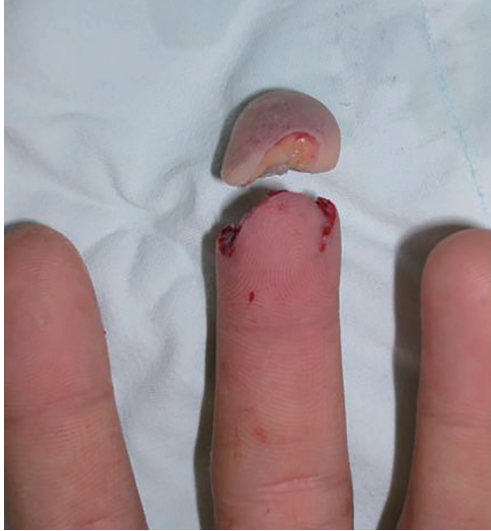

Fig. 1.
A preoperative clinical photograph. The preoperative clinical photograph shows volar oblique amputation in zone I.

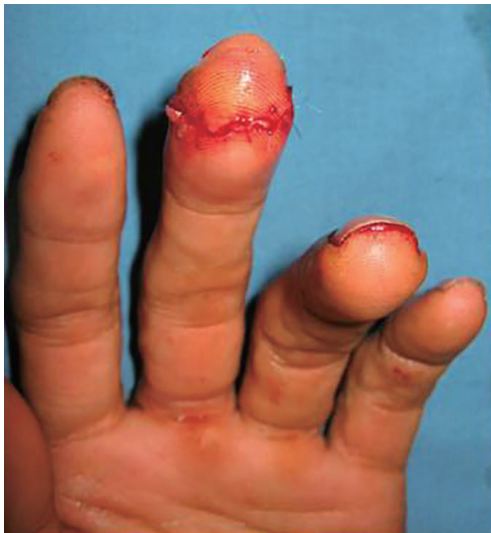

Fig. 2.
An intraoperative clinical photograph. This clinical photograph taken immediately after the surgery shows successful replantation.

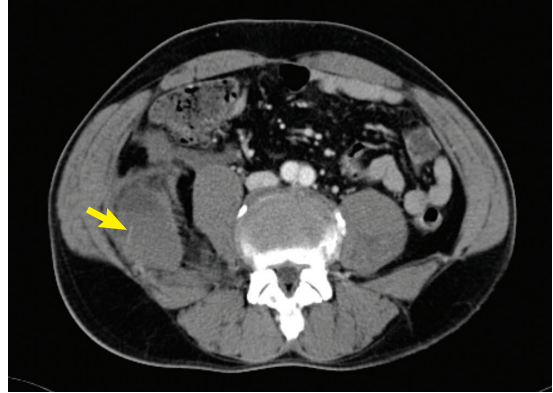


Fig. 3.
A computed tomography (CT) image of the hematoma. A transverse CT image of the abdomen shows an 8 cm × 3.6 cm loculated hematoma of the right iliacus muscle (yellow arrow).

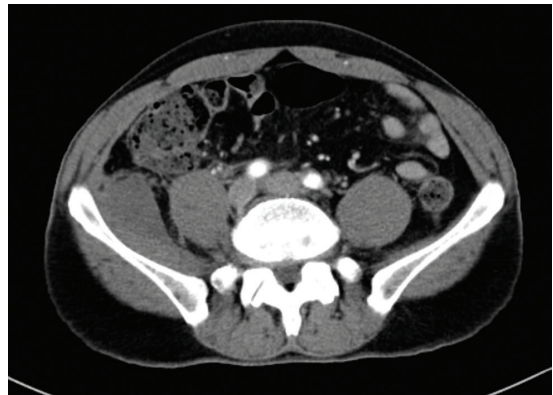

Fig. 4.
A computed tomography (CT) image shows the regression of the hematoma. After 7 days, a CT image shows the regression of the hematoma of the right iliacus muscle.

the patient complained of sudden pain in the right flank. The pain was sudden in onset, was severe, and did not respond to analgesics, but femoral neuropathies such as muscle weakness, paresthesia, and paralysis were not present. Although the patient's vital signs were stable, a laboratory test showed that the hemoglobin levels had dropped from 11.6 to 10.1, and then to 9.6 g/dL, within 12 hours. The leukocyte count was normal (7,800–9,520 mm³) and aPTT was delayed at 98.8 seconds. The computed tomography (CT) scan of the abdomen revealed an 8 cm × 3.6 cm hematoma of the right iliacus muscle combined with perilesional fluid collection and the widening of the retroperitoneal space and anteromedial displacement of the psoas muscle (Fig. 3). Fortunately, the hematoma was determined to be non-active bleeding

on the CT scan, and a conservative approach was followed. Heparin was stopped immediately, and aggressive pain control was initiated. The patient's laboratory test results stabilized within 12 hours after heparin was stopped: hemoglobin levels increased to 10.2 g/dL, and aPTT was within the normal range at 24 seconds. Follow-up CT 7 days later showed decreased hematoma with regression of the displacement of the psoas muscle (Fig. 4). The patient was discharged 17 days after surgery and 12 days after the onset of hematoma, with a stable hemoglobin level of 11.3 g/dL and aPTT of 26.9 seconds. At the time of discharge, his right flank pain had resolved and finger replantation was successful (Fig. 5).

Although anticoagulation is considered a crucial part of microsurgery, the protocols vary widely

among microsurgeons, and the most effective protocol has not yet been established. In order to maintain patency of and blood flow into the replanted tissue, microsurgeons use anticoagulation agents such as aspirin, dextran, and heparin [3].

Aspirin inhibits platelet aggregation. Perioperative administration of aspirin prevents microvascular thrombosis at anastomosis sites. Dextran is composed of variously sized polysaccharides. The antithrombotic effect of dextran reduces erythrocyte aggregation and platelet adhesion. Heparin is the most widely used agent for preventing vascular thrombosis. By binding to antithrombin III, heparin inhibits the activation of coagulation factors V and VIII, the recruitment of platelets, and the formation of fibrin. An increase in the blood clotting time and the elongation of aPTT are the clinical parameters involved in the antithrombin effect of heparin. A two-fold increase in aPTT is considered to be within therapeutic heparin levels. However, the use of heparin requires cautious monitoring because of the increased risk of hematoma [3]. Heparin is associated with hemorrhages of various sites, such as the lung, pericardium, gastrointestinal tract, adrenal glands, muscles, neural tissue, ocular orbits, corpus luteum, and anterior chest wall, which results in major bleeding in 7% of patients and fatal bleeding in 3% of patients. The risk of hemorrhage is not associated with the levels of heparin administered and occurs even at therapeutic levels. Only patient-related factors, such as renal failure, low body weight, or excessive alcohol consumption, are correlated with hemorrhage [1].

Iliopsoas hematoma is a rare complication associated with bleeding diathesis, trauma, and anticoagulant treatment [4]. Although hemorrhage is usually unilateral, a few cases report bilateral hematoma [1,2,5]. Diagnosis is based on clinical features and imaging studies, such as ultrasonography and CT [2,5]. Contrast-enhanced CT is the most sensitive method for the confirmation of hematoma. Early diagnosis is important because early treatment results in better recovery and fewer complications [4,5]. The treatment of iliopsoas hematoma starts with conservative management, including bed rest, volume replacement, and drug discontinuation. Conservative management is usually sufficient in cases with small hematomas and mild femoral neuropathy associated with non-active bleeding [2,5]. However, for patients with severe hemorrhage and intensive neurological symptoms, surgical

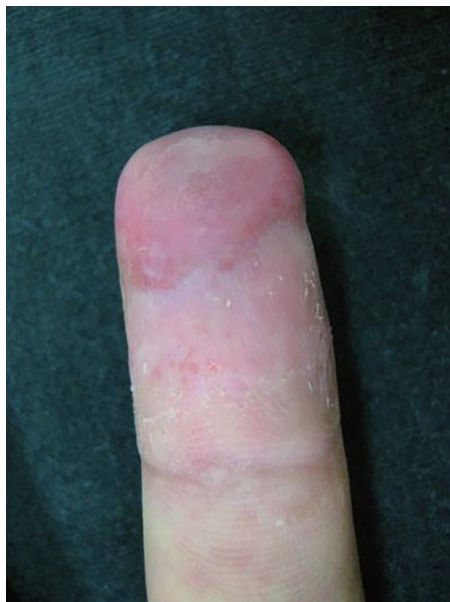

Fig. 5. A postoperative clinical photograph. The volar aspect of the middle finger (6 weeks after replantation) is well healed.

intervention is necessary. Some researchers have introduced transcatheter arterial embolization (TAE) as an alternative procedure for patients who are hemodynamically unstable or have surgical risk factors, since TAE treatment has been proven to be more successful and safer than surgery [1,5].

Our patient complained of sudden pain in the right flank without neurologic symptoms. Iliopsoas hematoma was diagnosed on the basis of CT and managed promptly, before the development of femoral nerve palsy. Our patient responded very well to conservative treatment, and his hemoglobin level and coagulation profile improved to normal values within 12 hours. Iliopsoas hematoma did not affect the patient's hospitalization, treatment of finger replantation, or course of recovery.

Patients undergoing treatment with heparin should be closely monitored for pain in the abdominal or inguinal areas, and femoral neuropathy. The rare complication of iliopsoas hematoma can occur in otherwise healthy patients. This is the first report of iliopsoas hematoma in a patient undergoing anticoagulant therapy after finger replantation who was successfully treated by conservative management. Early recognition led to early diagnosis by CT, which was crucial for early management and for avoiding morbidity.

References

1. Wada Y, Yanagihara C, Nishimura Y. Bilateral iliopsoas hematomas complicating anticoagulant therapy. Intern

- Med 2005;44:641-3.
2. Ozkan OF, Guner A, Cekic AB, et al. Iliopsoas haematoma: a rare complication of warfarin therapy. *J Coll Physicians Surg Pak* 2012;22:673-4.
 3. Askari M, Fisher C, Weniger FG, et al. Anticoagulation therapy in microsurgery: a review. *J Hand Surg Am* 2006;31:836-46.
 4. Sasson Z, Mangat I, Peckham KA. Spontaneous iliopsoas hematoma in patients with unstable coronary syndromes receiving intravenous heparin in therapeutic doses. *Can J Cardiol* 1996;12:490-4.
 5. Levin LS, Cooper EO. Clinical use of anticoagulants following replantation surgery. *J Hand Surg Am* 2008;33:1437-9.