

procedure has logistic and economic advantages over the two-stage procedure [2]. However, some other surgeons advocate the use of the one-stage procedure. The largest case series on this topic was published in Taiwan, with 34 cases: 28 one-stage and six two-stage procedures. In this case series, the occlusion rate in the one-stage procedure group was 29%, with an 11% flap failure rate, whereas 50% of the two-stage loops occluded, with a 33% flap loss rate. The authors demonstrated that two-staged arteriovenous loop is even more disappointing from the point of flap survival [2].

In summary, the use of an arteriovenous loop makes a neovascular system possible and is a useful method for solving unexpected vascular problems at an inadequate recipient site. Therefore, we conclude that an arteriovenous loop can be used as a breakthrough tool to overcome unexpected problems of micro-reconstruction in poorly vascularized lower extremities.

References

1. Hallock GG. The interposition arteriovenous loop revisited. *J Reconstr Microsurg* 1988;4:155-9.
2. Cavadas PC. Arteriovenous vascular loops in free flap reconstruction of the extremities. *Plast Reconstr Surg* 2008;121:514-20.
3. Freedman AM, Meland NB. Arteriovenous shunts in free vascularized tissue transfer for extremity reconstruction. *Ann Plast Surg* 1989;23:123-8.
4. Vlastou C, Earle AS. Short saphenous vein grafts as an aid to microsurgical reconstruction of the lower extremity. *J Reconstr Microsurg* 1988;4:145-54.
5. Lind B, McCarthy W, Derman G, et al. Arteriovenous loop grafts for free tissue transfer. *Vasc Endovascular Surg* 2012;46:30-3.

Segmental Hemihyperplasia-Related Macroductyly with Congenital Renal Agenesis: A Hand Surgeon's Point of View

João Nunes da Costa, Júlio Matias

Department of Plastic, Reconstructive and Maxillofacial Surgery, Hospital de Egas Moniz, Lisbon, Portugal

Correspondence: João Nunes da Costa

Department of Plastic, Reconstructive and Maxillofacial Surgery, Hospital de Egas Moniz, Rua Diogo de Silves, 35, 5.º Esq - 1400-107 Lisbon, Portugal
Tel: +35-1919828668, Fax: +35-1210432050, E-mail: jlnco@icloud.com

No potential conflict of interest relevant to this article was reported.

Received: 17 Feb 2015 • Revised: 13 May 2015 • Accepted: 1 Jun 2015

pISSN: 2234-6163 • eISSN: 2234-6171

<http://dx.doi.org/10.5999/aps.2015.42.5.655> • Arch Plast Surg 2015;42:655-658

Copyright © 2015 The Korean Society of Plastic and Reconstructive Surgeons

This is an Open Access article distributed under the terms of the Creative Commons Attribution Non-Commercial License (<http://creativecommons.org/licenses/by-nc/3.0/>) which permits unrestricted non-commercial use, distribution, and reproduction in any medium, provided the original work is properly cited.

Hemihyperplasia is a clinical condition defined as an asymmetric enlargement of one side of the body, usually in the upper and lower extremities, head, trunk, and internal organs. It may affect the entire hemibody or be segmental, and can present in a unilateral or crossed manner. Hemihyperplasia has a calculated incidence of 1:86,000 newborns [1] and is usually sporadic, but some familial occurrences have been described. It can be associated with a syndrome or be isolated, the latter usually being a diagnosis of exclusion. When affecting the hand, hemihyperplasia

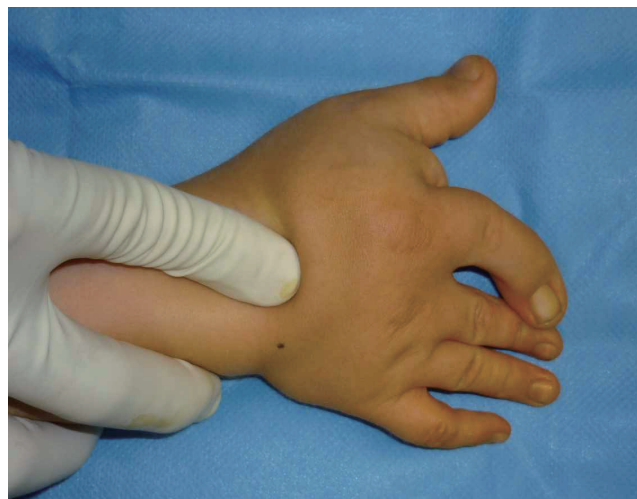

Fig. 1.

Patient at two years of age, showing right hand radial side macroductyly with index finger clinodactyly.

may be accompanied with macrodactyly. Although there are authors that reserve the term “macroductyly” solely for nonsyndromic, isolated digital overgrowth, it can also be used when associated with other pathologies, the most important to acknowledge being the Proteus syndrome, neurofibromatosis type 1, Klippel-Trénaunay-Weber syndrome, polyostotic fibrous dysplasia, Ollier disease, hemihyperplasia, hemangioma, Milroy disease, and Maffucci syndrome.

Macrodactyly is a rare disease affecting the hand and less frequently, the foot, with a calculated prevalence of 0.08 per 10,000 newborns. Macrodactyly is usually unilateral, with more than one finger affected, usually the second or the third [2]. Syndactyly may also be present.

Treatment options for macroductyly include vigilance (in mild cases), soft tissue debulking, nerve stripping, epiphysiodesis, osteotomies and bone shortening procedures, and phalangectomy, and in selected cases, digital transposition, toe transfer, or amputation. The results of surgery are often unsatisfactory, particularly if the disease is progressive and recurrent deformity is frequent, with the need for multiple interventions. Nevertheless, surgery is required in many cases on functional and aesthetic grounds.

Renal involvement is known to be associated with overgrowth conditions including tumors [3] and some genitourinary anomalies, but very rarely with unilateral renal agenesis. We found only one case in our literature review, and it was associated with complete hemihyperplasia in a patient with a probably atypical form of the Klippel-Trénaunay-Weber syndrome [4]. Unilateral renal agenesis is defined as the one-sided congenital absence of renal tissue resulting from the failure of embryonic kidney

formation. It has a calculated incidence of around 1:2,000 and is associated with musculoskeletal anomalies in 13% of cases [5]. To the best of our knowledge, no other cause of macroductyly has been reported along with unilateral renal agenesis. Although a statistical possibility, it is extremely improbable that the association of both conditions (hemihypertrophy and unilateral renal agenesis) is coincidental.

Fig. 1 shows the right hand of a male child with segmental hemihyperplasia of the right forearm and hand, associated thenar muscular hyperplasia, and thumb and index finger macroductyly, the latter with ulnar clinodactyly. The soft tissue volume of the right forearm is increased, although the radius and ulna length and diameter are similar on both sides, with no relevant loss of function. Congenital right renal agenesis was identified with echography and confirmed with a computed tomography (CT) scan (Fig. 2); right congenital dacryocystitis was also diagnosed. Genetic counseling could not establish a definite diagnosis, and the criteria for the Proteus syndrome were not met. No other members of the family were affected by similar or related symptoms. Throughout the years, the patient’s left renal function and morphology have remained normal. A delay in language development was also identified as the child grew; the patient was referred to a speech therapist and showed improvement.

When the patient was less than two years of age, due to the rapid growth of the affected fingers, we opted for volume reduction of the thenar region and the index finger (with perineural dissection of the radial side), and epiphysiodesis with an associated closing wedge resection of the middle phalanx to correct the clinodactyly. The result was satisfactory during the first year, but then, again, there was overgrowth of the index finger with ulnar deviation, conditioning the obvious functional limitation. With time, the inability of the extension and flexion of the finger also worsened. At 4 years of age, the patient was recommended further surgery because of the extent of clinodactyly and hypertrophy. Again, we performed dermo adipose volume reduction with perineural dissection of the index finger and the thenar region, volumetric reduction of the muscle groups of the thenar region, correction of the index finger’s clinodactyly with wedge osteotomy of the proximal phalanx (including the growth plate), and distal interphalangeal arthrodesis. The affected digital nerves (DI and DII) had a significantly larger caliber,

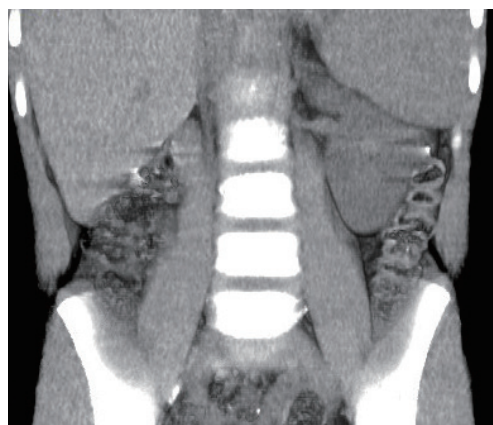


Fig. 2.
Volume rendering of a computed tomography scan showing the absence of the right kidney.

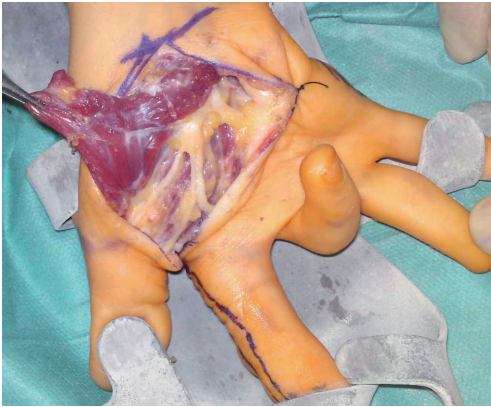


Fig. 3. Perioperative view of the thenar musculature hyperplasia and digital nerve enlargement during the second surgery.

and the musculature of the thenar region showed considerable hypertrophy, in contrast with a less marked adipose component (Fig. 3).

The patient is now 6 years old, and the longitudinal growth of the index finger seems to be under control (Figs. 4, 5). Clinodactyly correction was satisfactory, but ligament and tendon imbalance led to an impingement of the index finger over the third to the fifth fingers when the hand closed. The patient is left-handed but is able to perform a gross pinch with the right hand and uses this hand to perform some bimanual activities.

The literature shows that recurrence is very frequent in macrodactyly, and although there are many surgical options available, none have shown consistently good and reproducible results. Some authors defend that early amputation, particularly in the second digital ray, may lead to better functional results. Since our patient was only 6 years of age, and the finger size progression was moderate, we decided to wait for the growth of the remaining hand before embarking on more radical measures.

The question that remains is whether the carrying out of the epiphysiodesis of the proximal and middle phalanges was the reason that the index finger growth rate was not extreme, or whether it was independent of surgery. Nevertheless, we believe that an early approach can be recommended if any other problem exists, since it can justify surgery for reasons other than epiphysiodesis. In our case, it was the pronounced clinodactyly and thenar bulkiness, and the limited index finger function at the time of the second operation, which led us to perform distal interphalangeal arthrodesis. Some degree of success

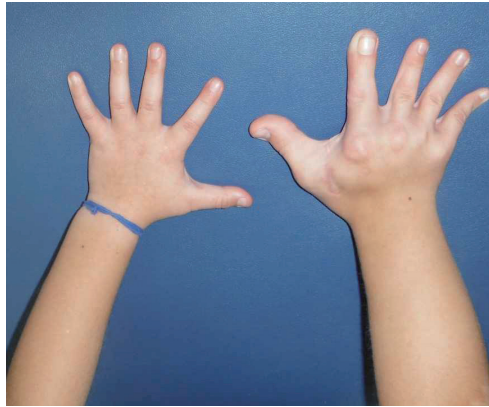


Fig. 4. Patient at six years of age, showing right forearm and hand segmental hemihyperplasia.

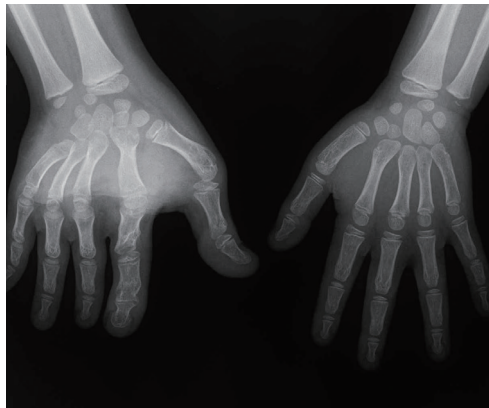

Fig. 5. X-ray at age six, with correction of clinodactyly and epiphysiodesis allowing the control of index finger overgrowth.

was attained two years after the last procedure. Thus far, the thumb function has been reasonable, although with a limitation of flexion; therefore, we have decided to continue with the regular follow-ups.

Symptomatic congenital nasolacrimal duct obstruction affects approximately 6% of otherwise healthy infants. Dacryocystitis may be uncommon, but given its incidence, we cannot honestly state that it is linked to the other problems reported and is not a coincidence. The same can be said about the delay in speech development.

We conclude that macrodactyly is a rare and difficult condition to treat, where the actual results often fall short of the desired ones. This is the second published case where hemihyperplasia is accompanied with unilateral renal agenesis and the first case where no other syndrome-related physical anomalies were found.

References

1. Parker DA, Skalko RG. Congenital asymmetry: report of 10 cases with associated developmental abnormalities. *Pediatrics* 1969;44:584-9.
2. Hardwicke J, Khan MA, Richards H, et al. Macrodactyly-

options and outcomes. *J Hand Surg Eur Vol* 2013;38:297-303.

3. Hoyme HE, Seaver LH, Jones KL, et al. Isolated hemihyperplasia (hemihypertrophy): report of a prospective multicenter study of the incidence of neoplasia and review. *Am J Med Genet* 1998;79:274-8.
4. Oren NC, Vurucu S, Karaman B, et al. Renal agenesis in a child with ipsilateral hemihypertrophy. *Pediatr Nephrol* 2010;25:1751-4.
5. Westland R, Schreuder MF, Ket JC, et al. Unilateral renal agenesis: a systematic review on associated anomalies and renal injury. *Nephrol Dial Transplant* 2013;28:1844-55.

Median Nerve Compression by the Feeding Vessels of a Large Arteriovenous Malformation in the Axilla

Kwang Seog Kim, Seung Ryeol Ji, Kyung Pil Kim, Yu Jin Kwon, Jae Ha Hwang, Sam Yong Lee

Department of Plastic and Reconstructive Surgery, Chonnam National University Medical School, Gwangju, Korea

Correspondence: Kwang Seog Kim
Department of Plastic and Reconstructive Surgery, Chonnam National University Medical School, 42 Jebong-ro, Dong-gu, Gwangju 61469, Korea
Tel: +82-62-220-6363, 6352, Fax: +82-62-227-1639
E-mail: pskim@chonnam.ac.kr

This article was presented at the 70th Congress of the Korean Society of Plastic and Reconstructive Surgeons on November 9–11, 2012 in Seoul, Korea.

No potential conflict of interest relevant to this article was reported.

Received: 16 Jun 2015 • Revised: 29 Jun 2015 • Accepted: 6 Jul 2015
pISSN: 2234-6163 • eISSN: 2234-6171
<http://dx.doi.org/10.5999/aps.2015.42.5.658> • Arch Plast Surg 2015;42:658-660

Copyright © 2015 The Korean Society of Plastic and Reconstructive Surgeons
This is an Open Access article distributed under the terms of the Creative Commons Attribution Non-Commercial License (<http://creativecommons.org/licenses/by-nc/3.0/>) which permits unrestricted non-commercial use, distribution, and reproduction in any medium, provided the original work is properly cited.

Arteriovenous (AV) malformations are fast-flowing vascular anomalies that bypass the capillary vessels and provide a supraphysiologic shunting path between arteries and veins. Such lesions most commonly occur in the head and neck area, with approximately 15% of cases occurring in the extremities [1]. Although various surgical treatments exist for AV malformations, curative resections are difficult due to the unclear surgical margins and propensity for bleeding. Moreover, recurrence is common. AV malformations have rarely been

reported to cause nerve compression syndrome, and the feeding artery has never been reported to cause median nerve entrapment. In this case report, we present the successful resection of a right axillary AV malformation in a patient with median nerve entrapment symptoms.

A 37-year-old male patient presented with a two-year history of a slowly growing mass in the right axilla and anterior chest wall (Fig. 1). He reported no significant medical history or familial medical history. This growth was associated with intermittent episodes of neurogenic pain that radiated from the right forearm to the fingers. The lesion was tender and erythematous with a palpable thrill and bruit. The patient also complained of pain with abduction and external rotation of the right shoulder joint. No muscle weakness was noted, so a preoperative electromyogram was not conducted.

Preoperative imaging included Doppler ultrasound, computed tomography, and magnetic resonance imaging (MRI) studies. The lesion was composed of two tortuous vascular structures connected with vessels and supplied by branches of the right axillary artery and internal mammary artery, respectively. The lesion drained into their venae comitantes and showed heterogeneous enhancement on a contrast-enhanced MRI scan (Fig. 2). The resection was performed under general anesthesia. The lesion was approached *via* an incision extending from the right axilla to the anterior chest. The normal tissue was dissected away from the lesion, with special care taken to protect the neurovascular structures. Two arteries rose from the axillary artery and internal mammary artery and fed into two separate masses. The median nerve was trapped between the axillary

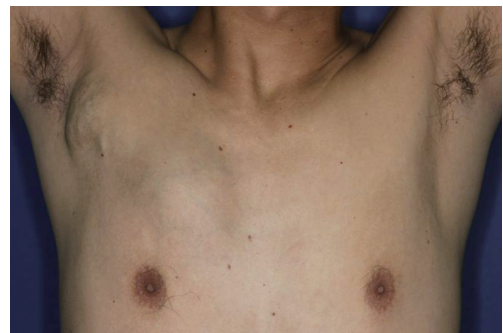

Fig. 1. Preoperative photograph. A 37-year-old man presented with subcutaneous masses consistent with large arteriovenous malformations of the right axilla and anterior chest.