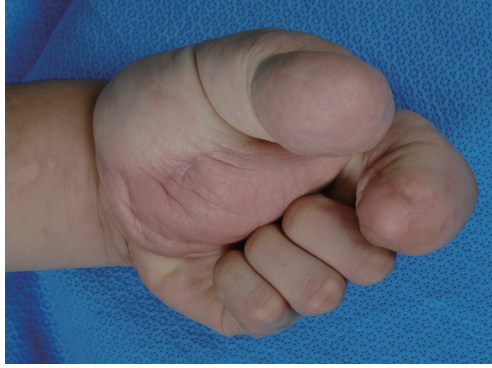



**Fig. 5.**

Postoperative opposing photographs. Opposing difficulty improved postoperatively. The patient could pick up objects more readily than before.

Neurofibromatosis can be diagnosed by a positive family history and certain characteristic cutaneous manifestations such as café-au-lait spots on the skin and soft tissue nodules. Furthermore, because bony overgrowth and fat deposition in subcutaneous tissues, tendons, muscles, and nerves with macrodactyly are specific diagnostic features of macrodystrophia lipomatosa, it can be differentiated from other diseases that can show similar clinical features.

Surgical intervention is the treatment of choice for macrodystrophia lipomatosa. The main surgical principle in treating these lesions is to improve the cosmetic appearance while preserving the neurologic function as much as possible. Through judicious and planned multiple debulking operations and partial amputations, good results can be achieved. However, surgery should be delayed until the patient's growth is complete if the deformity is not very serious and if no nervous system symptoms are present.

Complications associated with overzealous debulking procedures can lead to nerve injury; the reported incidence ranges from 30% to 50%. A localized recurrence rate of 33% to 60% makes the management of macrodystrophia lipomatosa demanding [5]. In our case, we achieved a satisfactory outcome in terms of functional recovery and the aesthetic results using debulking and amputation. However, we will continue to follow this patient to evaluate whether the symptoms regress to a static lesion or not.

## References

1. Goldman AB, Kaye JJ. Macrodystrophia lipomatosa: radiographic diagnosis. *AJR Am J Roentgenol* 1977; 128:101-5.

2. Soler R, Rodriguez E, Bargiela A, et al. MR findings of macrodystrophia lipomatosa. *Clin Imaging* 1997;21: 135-7.
3. Gupta SK, Sharma OP, Sharma SV, et al. Macrodystrophia lipomatosa: radiographic observations. *Br J Radiol* 1992;65:769-73.
4. Rohilla S, Jain N, Sharma R, et al. Macrodystrophia lipomatosa involving multiple nerves. *J Orthop Traumatol* 2012;13:41-5.
5. Brodwater BK, Major NM, Goldner RD, et al. Macrodystrophia lipomatosa with associated fibrolipomatous hamartoma of the median nerve. *Pediatr Surg Int* 2000;16:216-8.

## Malignant Peripheral Nerve Sheath Tumor Arising from Neurofibromatosis

Dae-Sung Lee, Sun-Il Jung, Deok-Woo Kim, Eun-Sang Dhong

Department of Plastic and Reconstructive Surgery, Korea University Guro Hospital, Korea University College of Medicine, Seoul, Korea

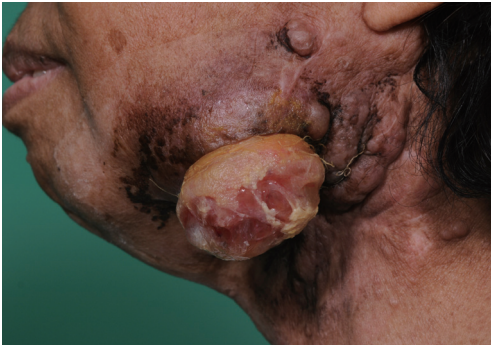**Correspondence:** Eun-Sang Dhong  
Department of Plastic and Reconstructive Surgery, Korea University Guro Hospital, Korea University College of Medicine, 148 Gurodong-ro, Guro-gu, Seoul 152-703, Korea  
Tel: +82-2-2626-1197, Fax: +82-2-852-7484  
E-mail: prsdhong@korea.ac.kr

No potential conflict of interest relevant to this article was reported.

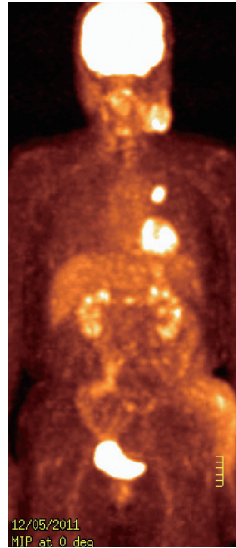
Received: 26 Nov 2012 • Revised: 14 Jan 2013 • Accepted: 16 Jan 2013  
pISSN: 2234-6163 • eISSN: 2234-6171  
<http://dx.doi.org/10.5999/aps.2013.40.3.272> • Arch Plast Surg 2013;40:272-275

Copyright © 2013 The Korean Society of Plastic and Reconstructive Surgeons  
This is an Open Access article distributed under the terms of the Creative Commons Attribution Non-Commercial License (<http://creativecommons.org/licenses/by-nc/3.0/>) which permits unrestricted non-commercial use, distribution, and reproduction in any medium, provided the original work is properly cited.

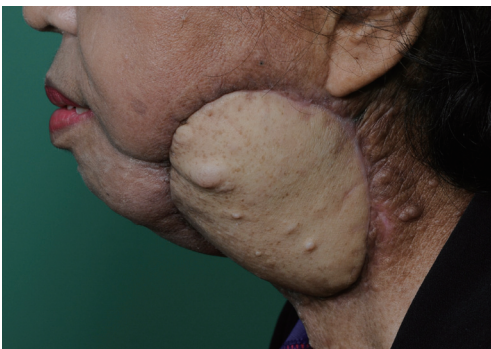Neurofibromatosis type 1 (NF 1) is an inherited autosomal dominant disorder with an estimated incidence of 1 in 2,500 to 3,000 live births [1]. Neurofibromas are benign peripheral nerve sheath tumors developed from the proliferation of fibroblasts and Schwann cells. Wallac [2] categorized neurofibromas into four types: cutaneous neurofibromas of the epidermis or dermis, subcutaneous neurofibromas that are deeper than the dermis, deep nodular neurofibromas, and diffuse plexiform neurofibromas [2]. The World Health Organization uses the term malignant peripheral nerve sheath

**Fig. 1.**

Preoperative view. The patient was a 59-year-old female who had a malignant peripheral nerve sheath tumor (MPNST) arising from neurofibromatosis. This is a preoperative clinical photograph of the lateral view of the MPNST.

**Fig. 2.**

Preoperative image. Hypermetabolic lesion considered to be a distant metastasis in the left upper lung was detected on the 18-F-fluorodeoxyglucose positron emission tomography-computed tomography scan.

**Fig. 3.**

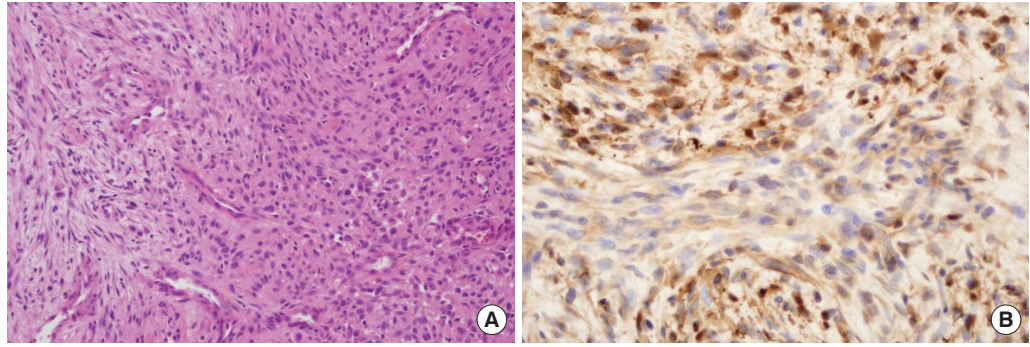
Postoperative view. Postoperative result 5 months after surgery.

tumor (MPNST) to describe tumors that were previously known as neurogenic sarcoma, neurofibrosarcoma, and malignant schwannoma. MPNST is the main cause of death in NF1 and occurs in 8 to 13% of NF1 patients during their life span [1]. MPNST has a dismal prognosis including a reported 5-year survival rate of less than 50%, a high risk of local recurrence (38% to 45%), and distant metastasis (40% to 80%) [1]. Despite the rarity of the disease, many clinical studies are devoted to MPNST because the patients are seen by many different specialists in various fields.

We present a case of a 59-year-old female patient who had malignant MPNST both on the neck and in the lung, which recurred from a previously removed neurofibromatosis. The cervical mass was initially excised ten years prior, and she has undergone frequent operations due to local recurrence despite undergoing postoperative radiation therapy twice, at approximately 60 Gy. At a recent admission, a red

dome-shaped tumor accompanying central ulceration on the previous operation site was discovered (Fig. 1). A lesion considered to be distant metastasis was also found in the lung based on a chest computed tomography (CT) scan and an 18-F-fluorodeoxyglucose positron emission tomography-CT scan (Fig. 2). There was no indication for the surgery, but she complained of discomfort during mastication and serous discharge from an ulcerated tumor. Therefore, a palliative operation instead of chemotherapy was selected to increase the quality of life. The decision was made to perform en bloc resection of the tumor with a 3 cm margin of healthy tissue under general anesthesia. Extended neck dissection and video-assisted thoracic surgical lobectomy of the left upper lung were also planned. The resulting defect was covered using a pectoralis major musculocutaneous flap in the same session. By postoperative day 14, total flap necrosis had gradually appeared, and selective debridement was performed in the operating room under the local anesthesia. Previous radiation therapy might be considered to be a cause of the flap necrosis. After two weeks, we performed a reoperation using anterolateral thigh free flap with the contralateral neck vessels. Nine months after treatment, the patient was still under observation. The patient was satisfied with the palliative surgery results and the increased quality of life. No local recurrence or complications have been found yet (Fig. 3). For the management of the patient's late-stage cancer, adjuvant radiotherapy or chemotherapy is considered as one of the palliative treatment options.

The excised tumor was grayish in color and

**Fig. 4.**

Histopathologic findings. Excised mass was diagnosed as a low-grade malignant peripheral nerve sheath tumor at this time. Note the hypercellularity and pleomorphism. (A) H&E ( $\times 50$ ), (B) S-100 staining ( $\times 50$ ).

necrotic in the central portion on gross appearance. On the section, the cut surface shows a whitish myxoid appearance with a focal yellowish myxoid area. The final histologic analysis revealed atypical spindle cells arranged in a fascicular pattern with slightly eosinophilic cytoplasm and hypercellularity with nuclear atypia (Fig. 4A). Immunohistochemically, S100 protein (Fig. 4B), vimentin, smooth muscle actin, and p53 in the tumor cells were positive, whereas C-Kit, human melanoma black 45, and p63 were negative. These findings were consistent with the diagnosis of MPNST arising in neurofibroma [3], and the same results were also found in the lung specimen.

Although multimodal therapy, including surgical resection, adjuvant radiotherapy, and chemotherapy, have been used for treatment of MPNST, the treatment guideline has not been established yet. Only surgical resection is the mainstay therapy, and it consists of wide resection of all the tissues affected by the tumor, along with safety margins, which are essential for local control [4]. Unfortunately, no study has investigated how the amount of excision with surgical margin would clarify the negative margin and improve the local control of disease. Until now, the surgeon has decided the surgical margin based on the preoperative image findings, intra-operative tissue findings, and surgical sites.

Radiation therapy is a highly important adjunct to surgery for improving local control, and it may be administered in the neoadjuvant or adjuvant manner and in an intraoperative setting [4]. Adjuvant chemotherapy has also been incorporated into the treatment modality to improve systemic control and to reduce the rate of distant metastasis. However, significant improvement in survival has not clearly been

demonstrated [4]. In a recent study of 175 patients diagnosed with MPNST at the Mayo Clinic, the use of adjuvant chemotherapy was associated with an improvement in the 5- and 10-year survival rate on univariate analysis, whereas neither adjuvant radiation nor chemotherapy had an impact on the survival rate on multivariate analysis [5]. In the Mayo Clinic study, the significant factors for predicting prognosis included a tumor size of  $\geq 5$  cm, a high tumor grade, the tumor location, the presence of NF1, local recurrence, and adjuvant chemotherapy on univariate analysis [5]. On multivariate analysis, a size of  $\geq 5$  cm, local recurrence, a high tumor grade, and truncal location were poor prognostic indicators for the 5- and 10-year survival rates [5]. Numerous previous studies confirm that carrying out definite wide excision, securing a negative margin, and adjuvant radiotherapy can reduce the local recurrence and increase the survival rate [4,5].

If the tumor is located adjacent to a vital organ, securing a sufficient negative margin may become difficult. Not securing an adequate excision margin, to avoid improper healing of the excision wound site, may be another reason for local recurrence of MPNST. Our patient had a MPNST with lung metastasis, and we performed a palliative operation for resolving the patient's complaints. Fortunately, to date, she has had good results. Though multimodal therapy including surgical resection and adjuvant radiotherapy is available for treatment of MPNST, the prognosis remains dismal. Early detection, surgery, and close observation were considered to be essential factors for treating MPNST. The treatment guideline for MPNST needs to be established in the near future.

## References

1. Evans DG, Baser ME, McLaughran J, et al. Malignant peripheral nerve sheath tumours in neurofibromatosis 1. *J Med Genet* 2002;39:311-4.
2. Wallace MR. Neurofibromatosis: phenotype, natural history, and pathogenesis, 3rd ed. edited by J. M. Friedman, David H. Gutmann, Mia MacCollin, and Vincent M. Riccardi. Baltimore: Johns Hopkins Press, 1999. Pp. 380. \$99.95 (hardcover only). *Am J Hum Genet* 2000;67:264.
3. Stark AM, Buhl R, Hugo HH, et al. Malignant peripheral nerve sheath tumours—report of 8 cases and review of the literature. *Acta Neurochir (Wien)* 2001;143:357-63.
4. Wong WW, Hirose T, Scheithauer BW, et al. Malignant peripheral nerve sheath tumor: analysis of treatment outcome. *Int J Radiat Oncol Biol Phys* 1998;42:351-60.
5. Stucky CC, Johnson KN, Gray RJ, et al. Malignant peripheral nerve sheath tumors (MPNST): the Mayo Clinic experience. *Ann Surg Oncol* 2012;19:878-85.

## Clinical Experience of Stewart-Treves Syndrome in the Lower Leg

Jung Ho Lee, Yeon Jin Jeong, Deuk Young Oh, Sang Wha Kim, Jong Won Rhie, Sang Tae Ahn

Department of Plastic Surgery, The Catholic University of Korea College of Medicine, Seoul, Korea

**Correspondence:** Deuk Young Oh

Department of Plastic Surgery, The Catholic University of Korea College of Medicine, 222 Banpo-daero, Seocho-gu, Seoul 137-701, Korea

Tel: +82-2-2258-6143 Fax: +82-2-594-7230

E-mail: ohdeuk1234@hanmail.net

No potential conflict of interest relevant to this article was reported.

Received: 3 Dec 2012 • Revised: 6 Mar 2013 • Accepted: 7 Mar 2013

pISSN: 2234-6163 • eISSN: 2234-6171

<http://dx.doi.org/10.5999/aps.2013.40.3.275> • Arch Plast Surg 2013;40:275-277

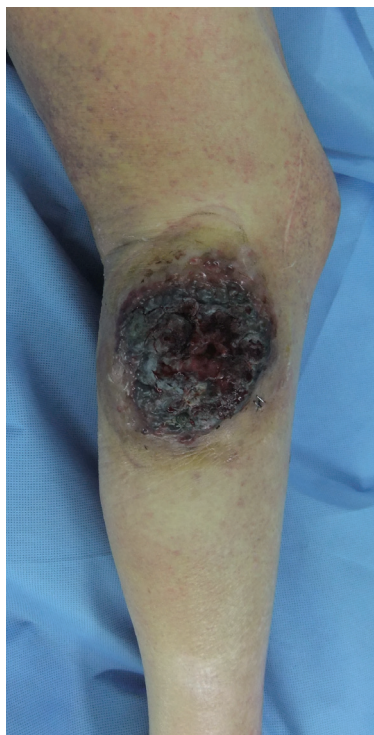Copyright © 2013 The Korean Society of Plastic and Reconstructive Surgeons

This is an Open Access article distributed under the terms of the Creative Commons Attribution Non-Commercial License (<http://creativecommons.org/licenses/by-nc/3.0/>) which permits unrestricted non-commercial use, distribution, and reproduction in any medium, provided the original work is properly cited.

Stewart-Treves syndrome is a kind of angiosarcoma associated with chronic lymphedema. It was first reported by Stewart and Treves [1] in 1948. In their study, they reported a series of six patients who had developed angiosarcoma in their lymphedematous extremities after radical mastectomy. The exact

mechanism of Stewart-Treves syndrome is not clear. It may be due, however, to the accumulation of protein-rich interstitial fluid in a chronically swollen limb [2]. This fluid alters the local immune environment of the chronically edematous limb and promotes lymphangiogenesis. It also aggravates the locally immunocompromised state to easily presented malignancy. The prognosis of Stewart-Treves syndrome has been regarded as poor due to its aggressiveness. The mean survival period from this disease has been quoted to be seven months, with an approximately 35% overall five-year survival rate [3]. Because of its aggressiveness and poor prognosis, early detection and surgical management are considered the key factors in the survival of patients.

In this article, a rare case of Stewart-Treves syndrome in the lower extremities that was misdiagnosed as a pressure ulcer is reported. A 72-year-old female was referred to the authors' clinic for the management of a protruding purple to black skin lesion with central ulceration, which developed about six months before the patient's presentation, in her right lower leg (Fig. 1). Her physical examination showed that the size of the lesion was about 9 cm × 8 cm, and there was a mild pitting edema in her right lower leg. Since the initial development of the lesion, the patient had been treated in the local clinic under the impression of



**Fig. 1.** Preoperative findings of a 9 cm × 8 cm purple to black protruding skin lesion with central ulceration on the upper lateral side of the right lower leg with diffuse edema.